

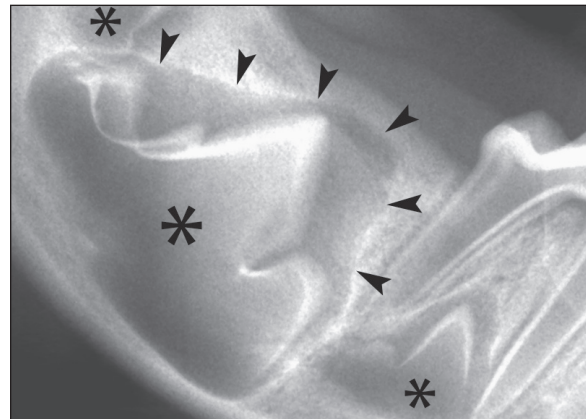
## An overview of dentigerous cysts in dogs and cats

Jérôme D'Astous

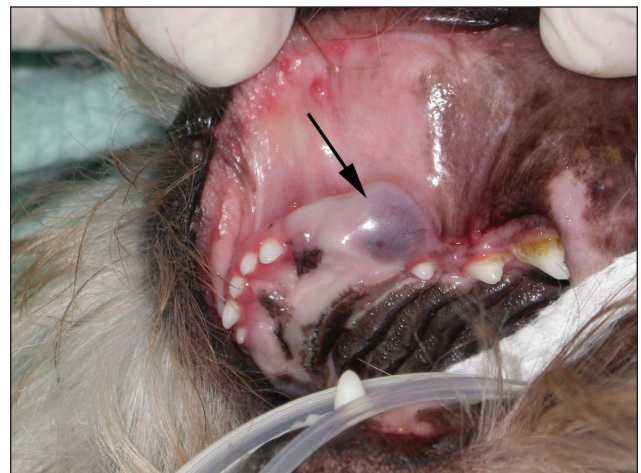**M**any dental diseases can be easily treated or even prevented if the diagnosis is made early. A simple example is the dentigerous cyst, although many veterinarians are not familiar with this condition. This article presents an overview of dentigerous cysts in dogs and cats, in the hope that more of these cysts will be prevented or diagnosed early.

Dentigerous cysts (follicular cysts) are, in my experience, the most common odontogenic cysts in dogs and cats, and are similar to those described in humans (1–3). Dentigerous cysts are associated with the crown of an unerupted tooth, usually a permanent tooth. They arise from the epithelial remnants of the enamel organ or the reduced enamel epithelium that surrounds the crown during odontogenesis (1,3) (Figure 1). Dentigerous cysts enclose the crown of the unerupted tooth and are attached to the tooth at the cemento-enamel junction. Unerupted teeth are usually a developmental problem due to a physical barrier (impacted tooth) or a lack of eruptive forces (embedded tooth) (4,5). An iatrogenic dentigerous cyst was also reported in a dog following the extraction of a deciduous tooth. The permanent tooth bud was damaged which resulted in a malformed impacted tooth (6).

Dentigerous cysts are more common in dogs than in cats (7). Brachycephalic dogs are more frequently affected and the condition is sometimes bilateral (5,8–12). Although these cysts could be associated with any tooth, the mandibular first premolar of the dog is the most frequent (8,10,11,13). The maxillary and mandibular canine are also often implicated (5). They can be diagnosed at any age but late diagnosis is usually associated with larger lesions. Affected animals often have no clinical signs apart from the absence of 1 or more teeth (hypodontia). These cysts are capable of achieving significant size, and their slow growth causes a thinning and expansion of the adjacent cortical bone. Facial asymmetry and an oral mass may then be observed. This mass may be fluctuant or hard on palpation depending on the presence or absence of a thin layer of bone over the cyst cavity. The soft tissues overlying the cyst generally have a normal appearance but can sometimes have a bluish tint, mainly with larger lesions (Figure 2). It is usually not associated with pain



**Figure 1.** Intraoral dental radiograph of a 2-month-old doberman pinscher showing the developing permanent tooth buds (asterisks). In the middle, the contour of the permanent right mandibular first molar crown is clearly visible. The radiolucent area around the crown with a well-defined margin represents the space that is occupied by the enamel organ (arrowheads).



**Figure 2.** Photograph of a 2-year-old shih tzu with a large dentigerous cyst (arrow) associated with an unerupted left maxillary canine. The condition was bilateral. The left maxillary third incisor and the left maxillary second premolar were absent on the radiographs. (Photograph courtesy of Dr. Yvan Dumais).

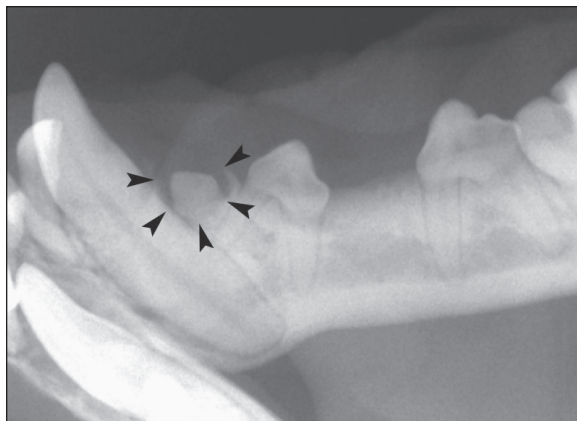
Centre Vétérinaire DMV, 2300 54E Avenue, Lachine, Québec H8T 3R2.

Address all correspondence to Dr. Jérôme D'Astous; e-mail: [jdastous@centredmv.com](mailto:jdastous@centredmv.com)

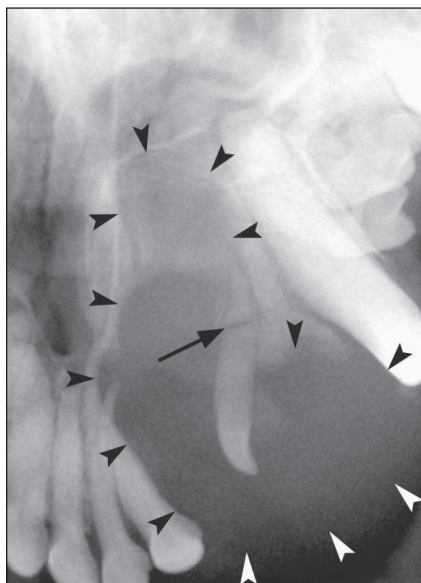
Use of this article is limited to a single copy for personal study. Anyone interested in obtaining reprints should contact the CVMA office ([hbroughton@cvma-acmv.org](mailto:hbroughton@cvma-acmv.org)) for additional copies or permission to use this material elsewhere.

unless it becomes infected. Dentigerous cysts can greatly weaken the surrounding bone or invade the nasal cavities. They may even cause pathological fractures (10,11,13).

During the initial oral examination, large dentigerous cysts may be mistaken for other common causes of oral swelling such as an abscess, a granuloma, a tumor or any other cystic lesion. If there is no bleeding, fine-needle aspiration of a dentigerous



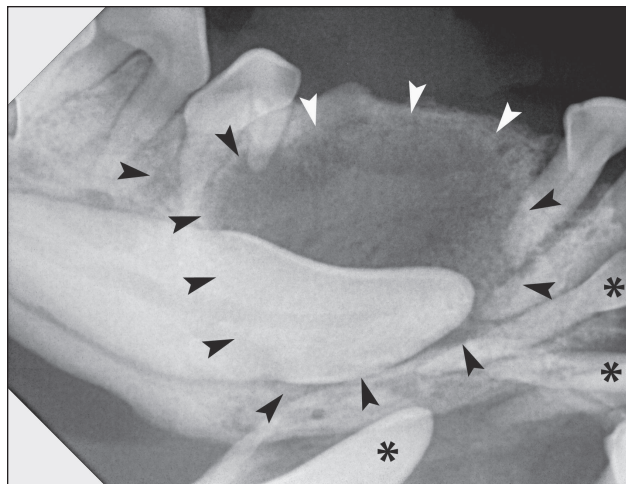
**Figure 3.** Intraoral dental radiograph of the unerupted left mandibular first premolar of a Japanese spaniel. A small dentigerous cyst (arrowheads) is seen enclosing the crown of this tooth. The left mandibular third premolar is absent.



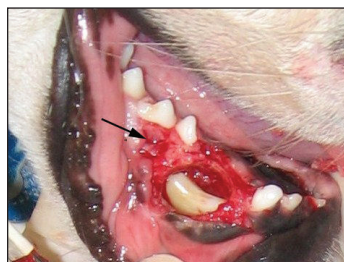**Figure 4.** Intraoral dental radiograph of a 6-year-old shih tzu. A large dentigerous cyst (arrowheads) has formed around the deciduous left maxillary third incisor. Note that its root is fractured (arrow). The permanent third incisor is absent. There is no more alveolar bone to support the second incisor. The cyst is invading the nasal cavity.

cyst will normally give a clear, yellowish to brownish, more or less viscous liquid. Cytology usually provides little additional information but may help to rule out other conditions, for example, bacterial infection. The diagnosis of a dentigerous cyst is essentially based on radiography and histopathology.

On radiographs, a dentigerous cyst typically appears as a circular radiolucent lesion with a well-defined cortex (fairly uniform, thin, radiopaque line) (2,14). This border could be less defined or missing if the cyst is infected (2). The lesion is usually unilocular and encloses the crown of an unerupted tooth (Figure 3). The shape and position of the tooth are often abnormal. The relationship of the cyst with the cemento-enamel junction is not always visible when the cyst becomes larger (Figure 4). The unerupted tooth and the adjacent teeth in contact with the cyst can have tooth resorption or be displaced



**Figure 5.** Intraoral dental radiograph of a 2-year-old Boston terrier. A large dentigerous cyst (arrowheads) is enclosing the crown of the unerupted right mandibular canine. Note the expansion of the mandible and also the resorption and displacement of adjacent teeth. The 2 first mandibular incisors and the left mandibular canine (asterisks) were also unerupted with an associated dentigerous cyst. The right mandibular first premolar is absent.



**Figure 6.** Intraoperative photograph of the dog in Figure 5. The crown of the unerupted right mandibular canine is seen through the osteotomy previously performed. The cyst was also protruding into the middle mental foramen (arrow).

(Figure 5). Although the radiographic findings are nearly pathognomonic (15), they are not diagnostic because other lesions may appear similar on radiographs (14). Histopathology is always recommended. In humans, the epithelial lining may, in rare cases, change into an ameloblastoma or a carcinoma (1). Carcinomas have also been found in the epithelium of odontogenic cysts in dogs (16). An ameloblastic fibro-odontoma has also been described in a dog in relation to a dentigerous cyst (17). In humans, it is also important to differentiate the dentigerous cyst from the odontogenic keratocyst, the latter having a higher rate of recurrence after excision (3).

The management of dentigerous cysts is simple and easily performed if the cyst is small. Extraction of the unerupted tooth and enucleation of the entire cyst wall is definitive therapy in most instances. Incomplete excision may lead to recurrence of the cyst which is then called a residual cyst. The excised tissue should be submitted to a pathologist for the reasons previously mentioned. In large lesions, marsupialization of the cyst wall may be performed in a first stage to allow continuous drainage and eventual reduction in cavity size, facilitating enucleation in a second stage (1,3,18). In my opinion, large lesions should be

referred to a specialist (Figure 6). Caution is required with the treatment of these cysts because important adjacent structures could be injured (for example, mental nerve). The use of bone graft material is usually not necessary to fill the cavity left by the cyst (9,12). Teeth adjacent to the cyst may require different treatments depending on whether or not there is tooth resorption, significant loss of the alveolar bone, or loss of the vascular supply. Not all unerupted teeth will develop a dentigerous cyst. Nevertheless, if for any reason an unerupted tooth is not extracted, a radiographic follow-up should be recommended since the formation of a dentigerous cyst is always possible in the future (10). This conservative approach is sometimes chosen for the geriatric patient in whom a tooth has not yet caused any problems. The prognosis of most dentigerous cysts is excellent. Radiographic monitoring is recommended to evaluate bone healing after excision.

In conclusion, the prevalence of dentigerous cysts appears to be low in general (8,11). Nevertheless, given the severity of lesions that can be caused by dentigerous cysts, **the absence of a tooth beyond the normal period of eruption should be confirmed by dental radiographs.** Early surgical treatment is simple and can prevent many complications. Other conditions may also be encountered when a tooth is apparently absent. For example, the tooth may have been resorbed or had the crown fractured and the root retained.

### Suggested reading

Ellis E. Surgical management of oral pathologic lesions. In: Hupp JR, Ellis E, Tucker MR, eds. *Contemporary Oral and Maxillofacial Surgery*. 5th ed. St. Louis, Missouri: Mosby Elsevier, 2008:449–468.

### References

1. Regezi JA, Sciubba JJ, Jordan RCK. *Oral Pathology: Clinical Pathologic Correlations*. 5th ed. St. Louis, Missouri: Saunders Elsevier, 2008:xiv, O75, 418.

2. White SC, Pharoah MJ. *Oral Radiology: Principles and Interpretation*. 6th ed. St. Louis, Missouri: Mosby/Elsevier, 2009:xiii, 641.
3. Neville BW. *Oral and Maxillofacial Pathology*. 3rd ed. St. Louis, Missouri: Saunders/Elsevier, 2009:xvi, 968.
4. Hoffman S. Abnormal tooth eruption in a cat. *J Vet Dent* 2008;25:118–122.
5. Okuda A, Eguchi T, Kishikawa Y, Ichihara N, Asari M. Review of 117 impacted (98 permanent and 19 deciduous) teeth in 46 dogs. *Proceedings, 21st Ann Vet Dental Forum* 2007:375–377.
6. Manfra Marretta S, Patnaik A, Schloss A, Kapatkin A. An iatrogenic dentigerous cyst in a dog. *J Vet Dent* 1989;6:11.
7. Gioso MA, Carvalho VG. Maxillary dentigerous cyst in a cat. *J Vet Dent* 2003;20:28–30.
8. Menzies RA, Lewis JR, Reiter AM. Long term follow-up of treatment for odontogenic cysts and odontogenic tumors of client-owned dogs. *Veterinary Dental Forum* 2010:417.
9. Bellezza E, Angeli G, Leonardi L, Rastrelli P, Di Mari W, Palazzoli G. A case of a mandibular dentigerous cyst in a German shepherd dog. *Vet Res Commun* 2008;32 Suppl 1:S235–237.
10. Soukup JW, Lawrence JA, Pinkerton ME, Schwarz T. Computed tomography-assisted management of a mandibular dentigerous cyst in a dog with a nasal carcinoma. *J Am Vet Med Assoc* 2009;235:710–714.
11. Baxter CJ. Bilateral mandibular dentigerous cysts in a dog. *J Small Anim Pract* 2004;45:210–212.
12. Watanabe K, Kadosawa T, Ishiguro T, et al. Odontogenic cysts in three dogs: One odontogenic keratocyst and two dentigerous cysts. *J Vet Med Sci* 2004;66:1167–1170.
13. Lemmons MS, Gengler WR, Beebe DE. Diagnostic imaging in veterinary dental practice. Unerupted tooth resulting in a dentigerous cyst causing resorption of bone. *J Am Vet Med Assoc* 2006;228:1023–1024.
14. DuPont GA, DeBowes LJ. *Atlas of dental radiography in dogs and cats*. 1st ed. St. Louis, Missouri: Saunders Elsevier, 2009:xi, 268 p.
15. Lobprise HB, Wiggs RB. Dentigerous cyst in a dog. *J Vet Dent* 1992;9:13–15.
16. Poulet FM, Valentine BA, Summers BA. A survey of epithelial odontogenic tumors and cysts in dogs and cats. *Vet Pathol* 1992;29:369–380.
17. Kramek BA, O'Brien TD, Smith FO. Diagnosis and removal of a dentigerous cyst complicated by ameloblastic fibro-odontoma in a dog. *J Vet Dent* 1996;13:9–11.
18. Ellis E. Surgical management of oral pathologic lesions. In: Hupp JR, Ellis E, Tucker MR, eds. *Contemporary Oral and Maxillofacial Surgery*. 5th ed. St. Louis, Missouri: Mosby Elsevier, 2008:449–468.