


This article was downloaded by: [186.177.46.7]

On: 09 September 2014, At: 22:04

Publisher: Taylor & Francis

Informa Ltd Registered in England and Wales Registered Number: 1072954

Registered office: Mortimer House, 37-41 Mortimer Street, London W1T 3JH, UK



Veterinary Quarterly

Publication details, including instructions for authors and subscription information:

<http://www.tandfonline.com/loi/tveq20>

Pathology of equine phycomycosis

A. Berrocal^a & T. S. G. A. M. van den Ingh^{b c}

^a Department of Veterinary Pathology , Universidad Nacional , Heredia, Costa Rica

^b Institute of Veterinary Pathology , State University , Yalelaan 1, Utrecht, The Netherlands

^c Institute of Veterinary Pathology , Yalelaan 1, Utrecht, 3508 TD, The Netherlands

Published online: 01 Nov 2011.

To cite this article: A. Berrocal & T. S. G. A. M. van den Ingh (1987) Pathology of equine phycomycosis, *Veterinary Quarterly*, 9:2, 180-184, DOI: [10.1080/01652176.1987.9694095](https://doi.org/10.1080/01652176.1987.9694095)

To link to this article: <http://dx.doi.org/10.1080/01652176.1987.9694095>

PLEASE SCROLL DOWN FOR ARTICLE

Taylor & Francis makes every effort to ensure the accuracy of all the information (the "Content") contained in the publications on our platform. However, Taylor & Francis, our agents, and our licensors make no representations or warranties whatsoever as to the accuracy, completeness, or suitability for any purpose of the Content. Any opinions and views expressed in this publication are the opinions and views of the authors, and are not the views of or endorsed by Taylor & Francis. The accuracy of the Content should not be relied upon and should be independently verified with primary sources of information. Taylor and Francis shall not be liable for any losses, actions, claims, proceedings, demands, costs, expenses, damages, and other liabilities whatsoever or howsoever caused arising directly or indirectly in connection with, in relation to or arising out of the use of the Content.

This article may be used for research, teaching, and private study purposes. Any substantial or systematic reproduction, redistribution, reselling, loan, sub-licensing, systematic supply, or distribution in any form to anyone is expressly forbidden. Terms & Conditions of access and use can be found at <http://www.tandfonline.com/page/terms-and-conditions>

Pathology of equine phycomycosis

A. Berrocal¹ and T. S. G. A. M. van den Ingh²

SUMMARY *The pathological findings in three cases of equine phycomycosis in Costa Rica are described. Two cutaneous (Pythium sp) and one nasal lesion (Conidiobolus) were observed.*

INTRODUCTION

Equine phycomycosis is a group of diseases caused by *Pythium* sp. (*Hyphomyces destruens*), class *Oomycetes*, kingdom *Protista*, *Basidiobolus haptosporus*, class *Zygomycetes*, kingdom *Fungi* and *Conidiobolus coronatus* (*Entomophthora coronata*), class *Zygomycetes*, kingdom *Fungi* (7).

Equine phycomycosis affects the skin and/or nasal mucosa of horses in tropical and subtropical parts of the world (6,8). It has been described in the U.S.A., Australia, Brazil, India and Colombia (5,6,8) and is known under various local names such as leeches, swamp cancer, *Espundia equina* and rhinophycomycosis. The present report describes the pathological findings in three cases of equine phycomycosis in Costa Rica and the local conditions predisposing to the disease.

CASE REPORTS

Gross lesions

Case 1.

A male, adult working horse from a farm in Canas (province of Guanacaste) had a tumorous mass surrounding the manubrium sterni. The diameter varied from 20-25 cm. The lesion contained thick sanguineouspurulent material that ran from fistulous tracts. Cut surfaces of the lesion were granulomatous and fibrous; many yellow-grey necrotic masses (leeches) and calcified nodules, diameter 0.25-1 cm were present.

Case 2.

An adult working mare from the same farm had an ulcerated lesion (20 x 15 cm) on the palmar aspect of the left carpal joint (Fig. 1). The lesion contained more exudate than in Case 1; the surface had several fistulae and was covered by vegetable material and detritus. The adjacent skin was alopecic. Cut surfaces of the lesion had a similar appearance to Case 1 with many yellow-grey granules of variable size (diameter 0.25-1 cm) and form.

Case 3.

An adult working mare, originating from a farm in Turrialba (province of Limon) was euthanised because of upper respiratory dyspnoea, which at post mortem examination was found to be caused by partial obstruction of the nasal passages.

¹ Department of Veterinary Pathology, Universidad Nacional, Heredia, Costa Rica

² Institute of Veterinary Pathology, State University, Yalelaan 1, Utrecht, The Netherlands.

Address for reprints: Dr. T. S. G. A. M. van den Ingh, Institute of Veterinary Pathology, Yalelaan 1, 3508 TD Utrecht, The Netherlands.

The nasal septum was deviated to the left side. The mucosa was diffusely thickened by granulomatous tissue. Several firm fibrous nodules were also present (Fig. 2). Necrotic granules of varying size and form were present in the granulomatous tissue.

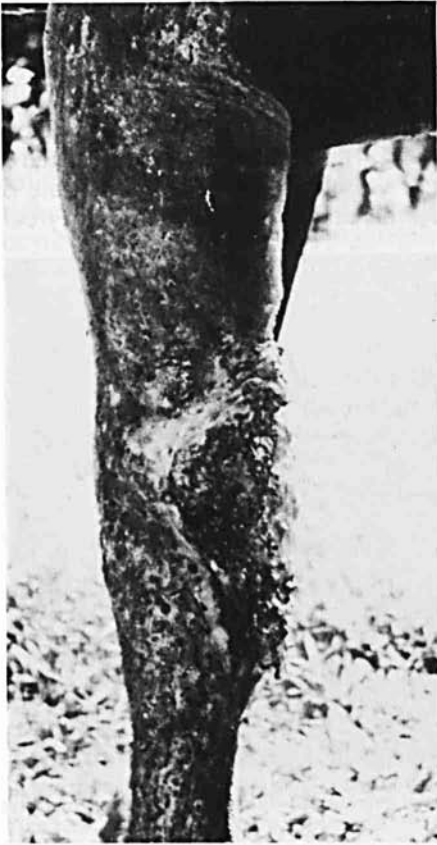

Fig. 1. Case 2. Ulcerative phytotic dermatitis behind the left carpal joint.

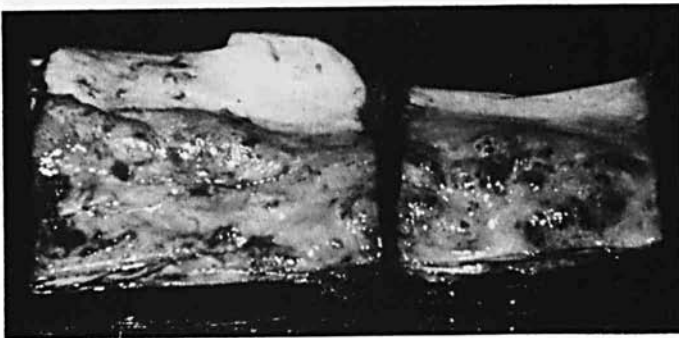

Fig. 2. Case 3. Irregularly thickened nasal septum caused by conidiobolomycosis.

Cases 1 and 2.

Both lesions consisted of fibrous tissue with scattered necrotic, strongly eosinophilic masses surrounded by an exudative inflammatory reaction with neutrophils, macrophages and some eosinophils (Fig. 3). These eosinophilic masses were composed of necrotic collagen and exudate and many mycotic hyphae were present throughout the necrotic material. The hyphae often extended from the eosinophilic necrotic masses into the surrounding exudate. They were 5-8 μm wide, branched, and rather thick-walled, and showed only scarce septation. Whereas the hyphae were difficult to see in haematoxylin and eosin sections, they were easily demonstrated in PAS and Grocott stained sections (Fig. 4). The fibrotic tissue consisted of newly formed collagen with proliferation of vessels and a varying infiltrate of lymphocytes, plasma cells and some neutrophilic and eosinophilic granulocytes.

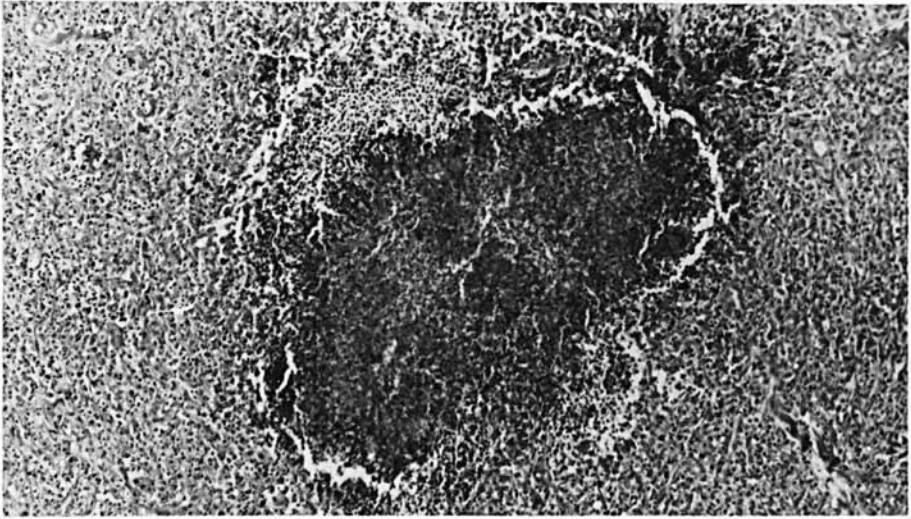


Fig. 3. Pythiosis. Necrotic eosinophilic mass (granule) surrounded by exudative and proliferative inflammation. HE 40 x



Fig. 4. Pythiosis. Necrotic collagen and several mycotic hyphae within a granule. Grocott 420 x.

Case 3.

The mucosa of the nasal septum was thickened due to chronic inflammation with abscesses and necrosis. The abscesses consisted mainly of eosinophilic granulocytes; also neutrophilic granulocytes and some scattered foreign body multinucleated giant cells were present.

Haemorrhages had resulted in a haemopurulent exudate. Within the exudate there were a few solitary hyphae, in most cases surrounded by eosinophilic amorphous material (Splendore - Hoespli phenomenon) (Fig. 5). The hyphae were easily demonstrated in PAS and Grocott stained sections (Fig. 6), and measured between 10 and 13 μm in diameter, had a thin wall, were septated and branched rarely. The surrounding eosinophilic material was also PAS positive. A localised necrotic mass, surrounded by macrophages and few multinucleated giant cells, contained a solitary hypha. The abscesses and necrotic mass were encapsulated by granulation tissue with reduced numbers of lymphocytes, plasma cells and eosinophilic granulocytes towards the periphery; aggregates of haemosiderin-laden macrophages were also present.

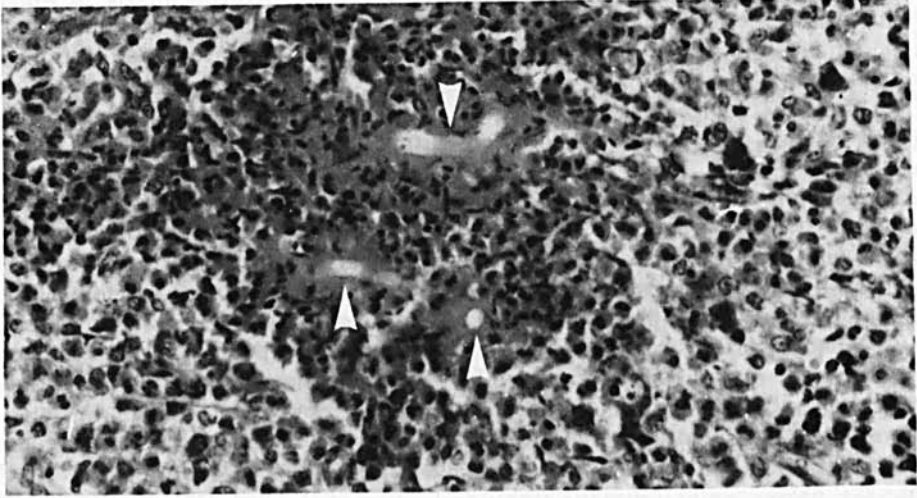


Fig. 5. Conidiobolomycosis. Three mycotic hyphae (arrows) with the Splendore-Hoespli phenomenon and surrounded by eosinophilic and neutrophilic granulocytes. HE 420 x.

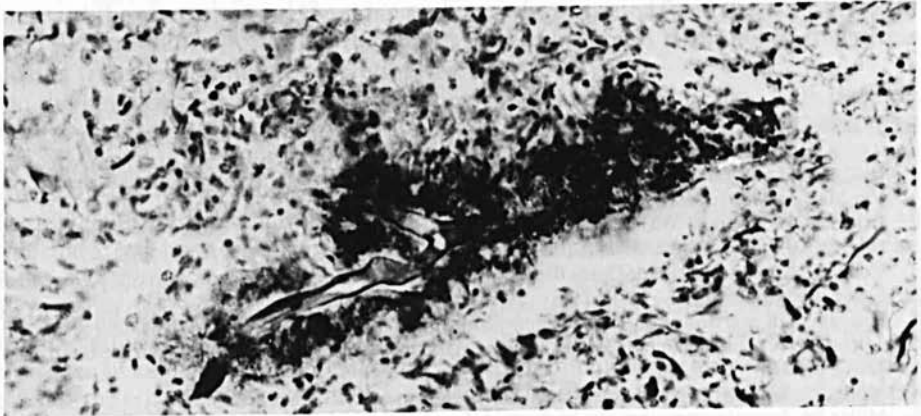


Fig. 6. Conidiobolomycosis. Transverse section of a thin-walled hypha with the Splendore-Hoespli phenomenon. Grocott 420 x.

DISCUSSION

The gross and histopathological findings are identical to those of equine phycomycosis (1,2,4,5,6,8). In Cases 1 and 2 the localisation of the lesions on the limbs and the ventral part of the trunk, the gross and histological features, the necrotic granules and the characteristic appearance of the hyphae are all consistent with *Pythium* sp (*Hyphomyces destruens*) infection. The nasal localisation, the gross and the microscopic features and the appearance of solitary hyphae with the Splendore-Hoeppli phenomenon in Case 3 are consistent with infection by *Conidiobolus coronatus* (*Entomophthora coronata*) (5, 6, 8).

Basidiobolus haptosporus is the third fungus incriminated in equine phycomycosis and belongs to the same family as *Conidiobolus coronatus*. Clinically the infection is similar to pythiosis although the lesions are most common on the lateral aspects of the trunk, chest, neck and head. The granules (leeches) are usually small or even absent. Histologically basidiobolomycosis is similar to conidiobolomycosis and also shows the Splendore-Hoeppli phenomenon around the fungal hyphae (8).

The most important differential diagnosis is cutaneous habronemiasis, in which yellow granules (leeches) may be present throughout the granulation tissue. Characteristic histological changes include nematode larvae with areas of eosinophilic coagulation necrosis (6).

The histopathological diagnosis of equine phycomycosis is only possible if leeches (granules) are included in the sample. Culture of the fungi from leeches is not difficult (7).

Pythium sp is an aquatic fungus. Its zoospores are discharged into the water and may invade and parasitise skin lacerations (7). This explains why most lesions in *Pythium* sp infection are located on the legs, ventral abdomen and trunk. Horses 1 and 2 are from a region which during the wet season (May through November) has about 250 mm of rain per month (3). During the dry season (January to March; 10-20 mm of rain per month) horses which do not work are sent to swamp areas to graze on the remains of green grass. In such areas there are usually also many different kinds of plants which can produce skin lacerations.

Conidiobolus and *Basidiobolus* are terrestrial fungi found in decaying organic material and soil in a hot moist climate. Infections probably occur by direct contact of nasal passages and traumatised skin respectively (7). The third horse originated from a region with between 200 and 400 mm of rain per month throughout the year (3).

REFERENCES

1. Bridges CH and Emmons CW. A phycomycosis of horses caused by *Hyphomyces destruens*. J Am Vet Med Ass 1961; 138: 579-89.
2. Bridges CH, Romane WM and Emmons CW. Phycomycosis of horses caused by *Entomophthora coronata*. J Am Vet Med Ass 1962; 140: 673-7.
3. Coen EP. Atlas estadístico de Costa Rica, Ministerio de Economía y Hacienda, Dirección General de Estadísticos y Censos.
4. Hutchins DR and Johnston KG. Phycomycosis in the horse. Austr Vet J 1972; 48: 269-78.
5. Johnston KG and Henderson AWK. Phycomycotic granuloma in horses in the northern territory. Austr Vet J 1974; 50: 105-7.
6. Miller RI. Equine phycomycosis. Comp Cont Education 1983a; 5: S472-S479.
7. Miller RI. Investigations into the biology of three 'phycomycotic' agents pathogenic for horses in Australia. Mycopath 1983b; 81: 23-8.
8. Miller RI and Campbell RSF. The comparative pathology of equine cutaneous phycomycosis. Vet Path 1984; 21: 325-32.