

UNILATERAL URETERAL FIBROEPITHELIAL POLYP IN A DOG

A. Berrocal¹, W. Moreno²

¹ Histopatovet, (www.histopatovet.com) A.P. 904-3000-Heredia, Costa Rica.

² Clínica Veterinaria Privada, Escazú, San José Costa Rica

INTRODUCTION

Primary ureteral neoplasias have been rarely described in human and domestic animals. In dogs only 15 documented ureteral neoplasias have been reported, eight of them as a fibroepithelial polyps. This polyp formation has been considered as a benign neoplasia or a chronic inflammatory reaction. They are usually unilateral and most frequently found in the proximal third of the ureter. Clinically, it is most associated with urinary incontinence, hydronephrosis and hydroureter and less with hematuria.

RESULTS

A-Clinical findings:

A 9-year-old, spayed female French poodle was presented with history of intermittent hematuria. At physical examination a distended abdomen was observed. At palpation a non-painful mass of 7.0-8.0 cms was found in the right caudal abdomen. All other parameters were normal. The mass was also observed by ultrasound. A laparotomy was performed to remove the mass that was attached to the right kidney by a long dilated tube structure. They were submitted already in formalin for histopathological examination.

B- Pathological findings:

Grossly: the kidney size was 10.0 cms. At cut surface it was filled with brown fluid and corticomedullary atrophy. Attached to the kidney there was a 22.0 cm long, dilated thin walled ureter ending with a 10.0 cm irregular mass partially attach to the mucosa obstructing the lumen. See figure 1.

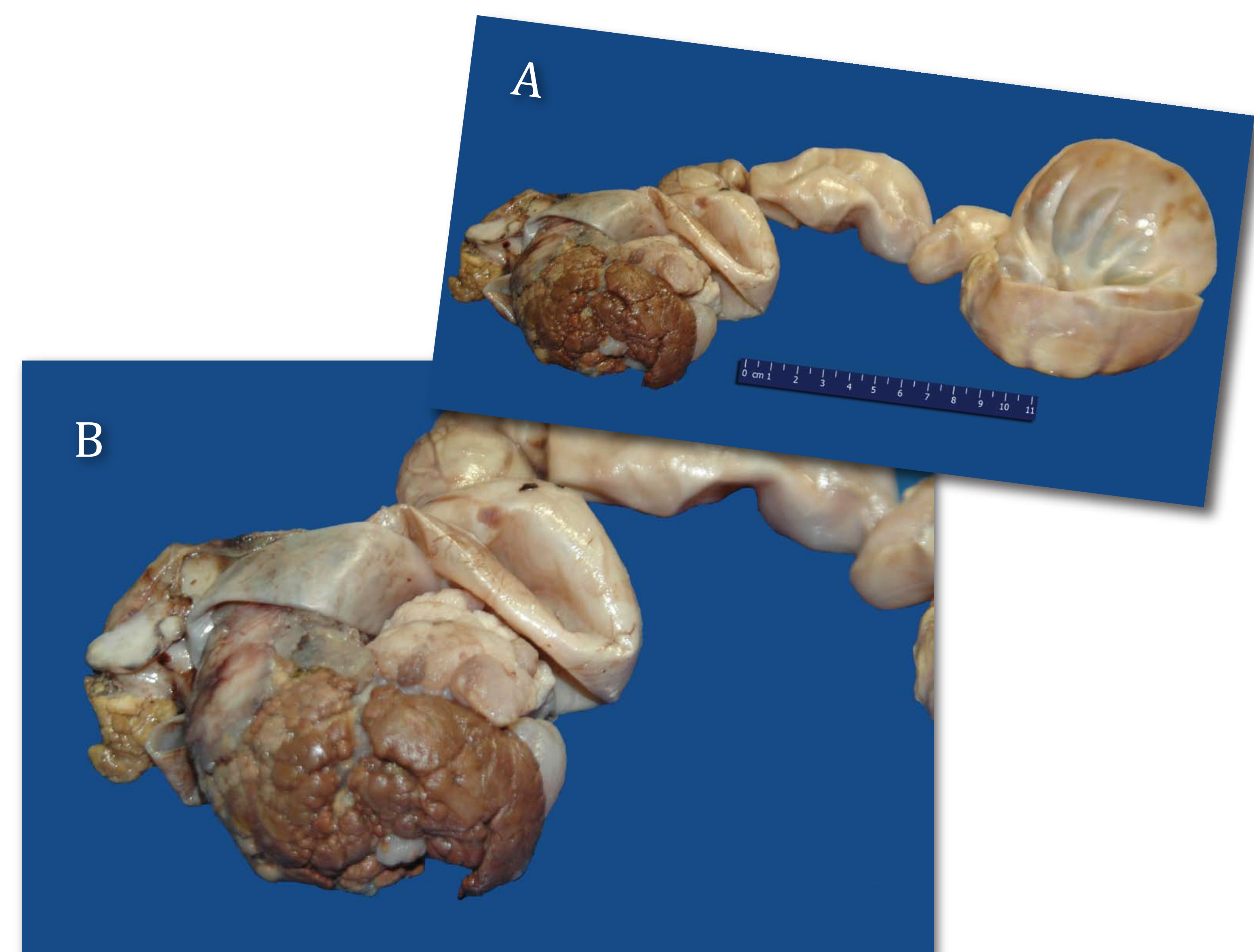


Fig. 1. After formalin fixation. Fig. A. It shows dilated kidney (hydronephrosis) and hydroureter. Fig. B. The mass with irregular surface.

Multiple samples of the kidney, ureter and the mass were fixed in 10 % buffered formalin. Then embedded in paraffin, sectioned at 5- μ m, and stained with hematoxylin-eosin and masson's trichrome. To characterize the case samples from the poly mass were deparaffinated and stained with immunohistochemical method using antibodies against vimentin clone Vim 3B4 and high molecular weight cytokeratin (CK-HMW) CLONE 34E1 β 2 (Biocare Medical, Inc.)

Histopathology: The kidney showed a complete atrophy of the pelvis and medulla, with a thin fibrotic cortex. The ureteral mass consisted of papillary fronds lined by transitional cell epithelium with vacuolization. Internally the fronds were composed predominantly by whorled spindle cells and new vessels most of them perpendicular to the surface. These microscopic features were better discerned by masson's trichrome and the immunohistochemical (vimentin and cytokeratin) See figure 2 and 3. Based on pathological findings, the final diagnosis was a ureteral fibroepithelial polyp with secondary hydroureter and hydronephrosis.

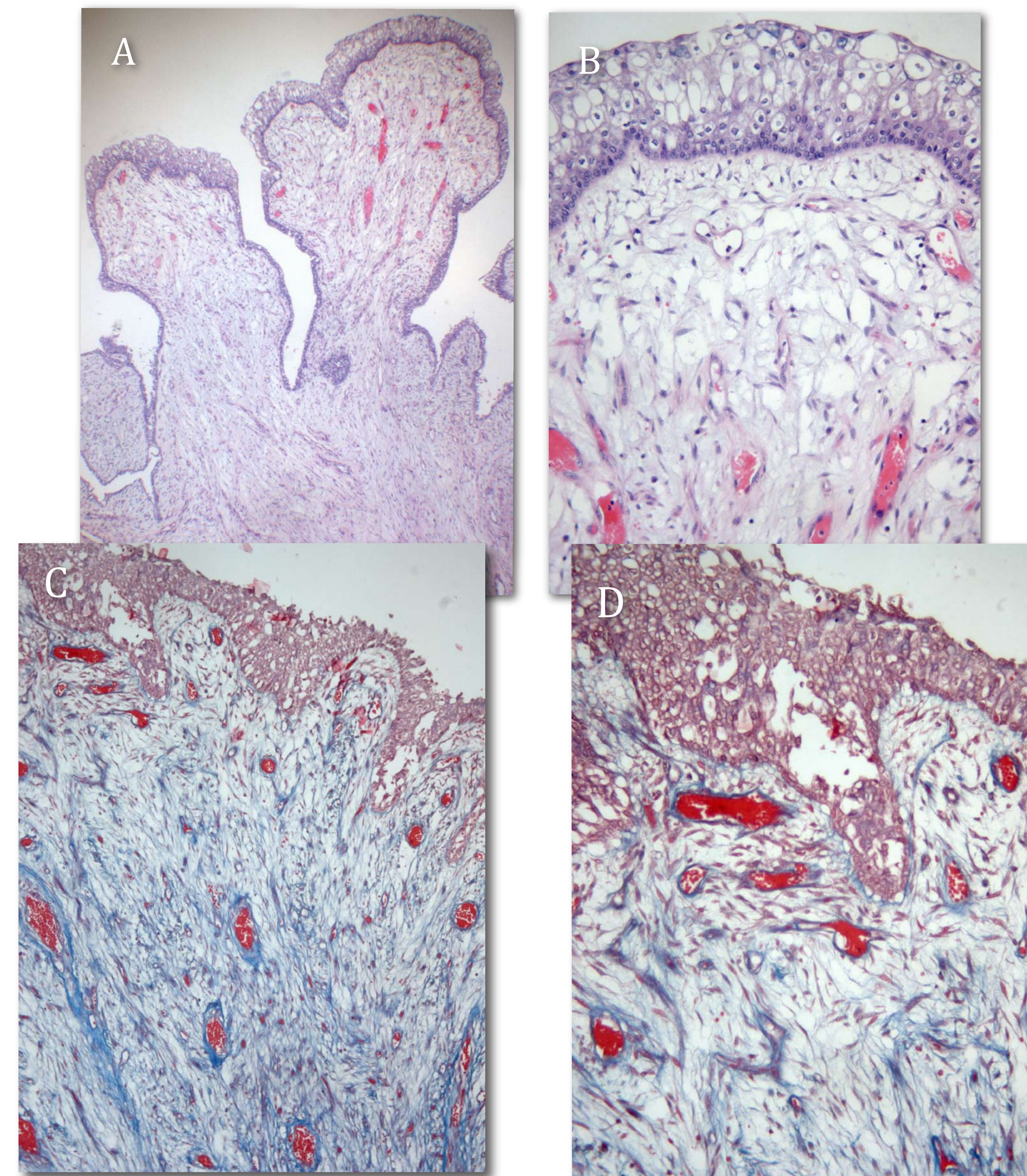


Fig. 2. A and B. The poly growth cover by transitional cells epithelium. The submucosa with a lot of fibrovascular tissue. H.E. stain. The figure C and D. The fibrous tissue is better seen by the masson's trichrome.

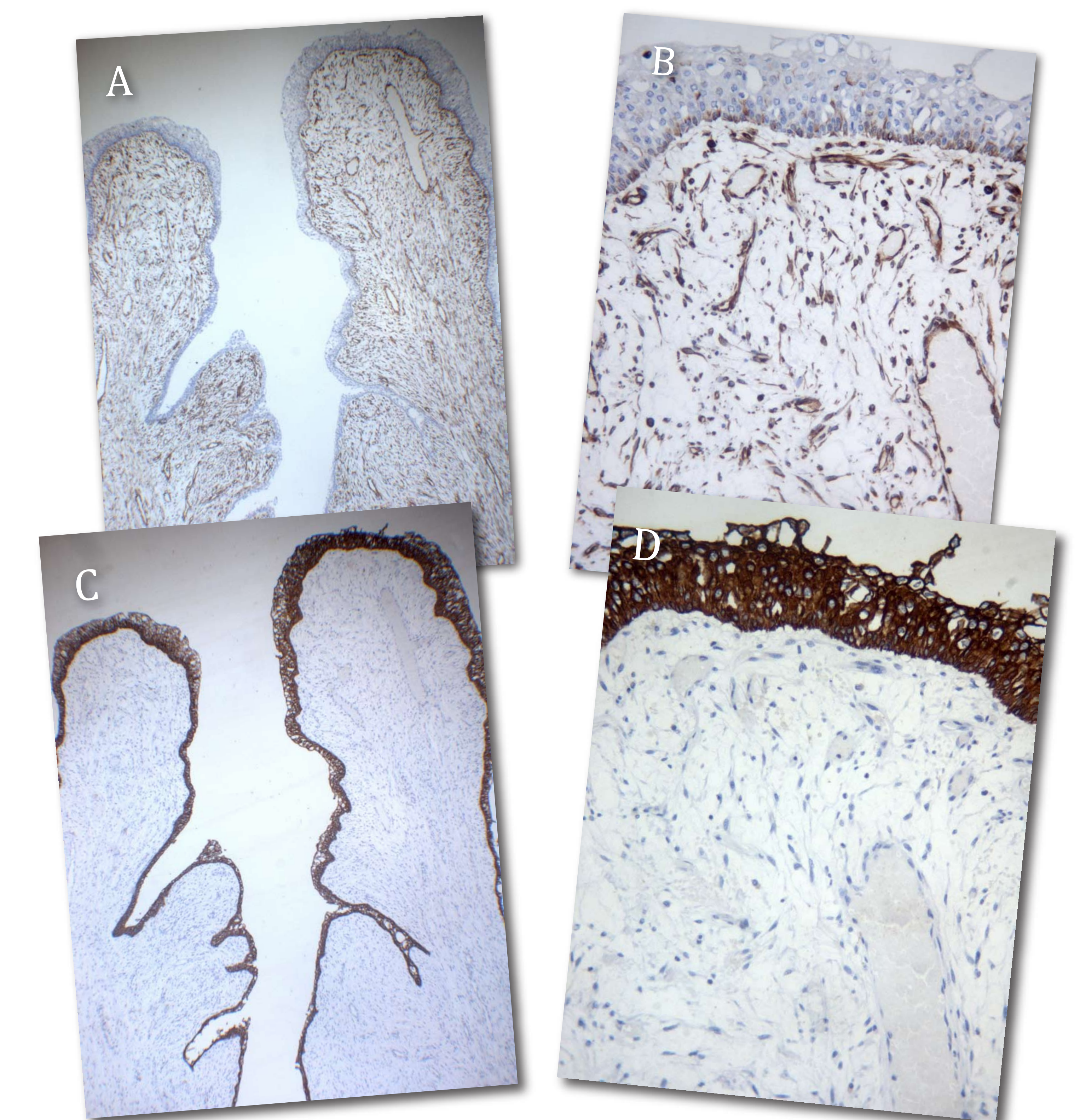


Fig. 3. Immunohistochemistry staining (monoclonal antibodies). Fig. A and B Vimentin. The figures C and D show the immunoreactivity to cytokeratin (see the positivity of transitional epithelium).

DISCUSSION AND CONCLUSION

Ureteral fibroepithelial polyps are uncommon in veterinary medicine as well as in humans. In fact this is the ninth case reported. Despite been a benign tumor clinically it is associated with urinary incontinence, infections, hematuria. Furthermore, hydronephrosis and hydroureter as it was observed in this patient is an important clinical and pathological finding attributable to obstruction of urine outflow.

REFERENCES

- Farrel, M., Philbey, A.W. and Ramsey, I. Ureteral fibroepithelial polyp in a dog. *Journal of Small Animal Practice*. (2006), 47, 409-412.
- Reichle, Jean K. et al. Ureteral fibroepithelial polyps in four dogs. *Veterinary Radiology & Ultrasound*. Vol. 44, No. 4, 2003, 433-437.

Acknowledgements: To Diego Castillo and Michael Cruz for reviewing the english manuscript.



Presented at: American Colleague Of Veterinary Pathology and ASVCP Annual Meeting in Minneapolis, Minnesota, U.S.A. On October 17-21, 2015.